



RESEARCH ARTICLE

A Role of Dental Radiograph in Human Forensic Identification

Dipali Rindhe¹, Prof. A.N. Shaikh²

^{1,2}Department of Electronics, SPWEC, Aurangabad, India

¹ dipalirindhe8943@gmail.com; ² aamer_be2005@yahoo.co.in

Abstract— Dental based human identification is commonly used in forensic. Dentistry can contribute for the identification of human remains after any disasters or crimes in assistance to other medical specialties. The algorithm can be developed by comparing post mortem and ante mortem dental radiographs. This work aims to introduce radiographic images. In this paper, a contour and skeleton-based shape extraction as well as matching algorithm for dental radiograph is proposed. An active contour model with selective binary and Gaussian filtering regularised level set method is used for contour extraction. Shape matching is done by both contour and skeleton-based approaches. The experimental results are obtained from a database of dental images include radiographs only. This algorithm provides better matching decision about the person than the existing algorithms since it includes skeleton measures also. The performance measures obtained and the hit-rate indicates that the better matching is observed with radiographic than the photographic images.

Keywords— dental radiograph; shape extraction; Shape matching; skeleton measures; Gaussian filtering

I. INTRODUCTION

Forensic odontology is a branch of forensics that deals with victim identification based on dental features. Owing to the evolution of information technology and an urge to investigate more cases by the forensic experts, it is necessary to automate the human identification system. Teeth are parts of human organ that are not easily decayed, located inside mouth and thus they are more protected from decaying after human's death. Therefore, teeth based identification is one of reliable tools for PM identification. On average, human has 32 teeth; each tooth has five surfaces, meaning that inside a mouth there are 160 tooth surfaces with various conditions. If we use dental features as a tool of identification, manual matching of AM with PM data needs a large amount of time and some expertise. Dental pattern can be considered as a biometric if there is no other means of physiological biometrics such as palm print, finger print, iris, face, leg print etc., are found. Human identification using dental images has been proven to be the best under certain circumstances if there is inaccessibility of other means of biometrics. Teeth and bones are treated as the hardest and robust tissues found in the human body, which yields resistant to modest force effects, high temperatures up to 1100°C.[7] It also possesses good biometric properties. It affords resistance to decay even in some critical situations as well as mass disasters such as bomb-blast, air-crash, major fire accident or flood etc.

II. LITERATURE REVIEW

Several studies are reported in literature for dental radiographs in human forensic identification. The work is as follows:

In year 2005, Hong Chen and Anil K. Jain perform a work “Dental Biometrics: Alignment and Matching of Dental Radiographs” [1] In this paper proposed system has two main stages: feature extraction and matching. The feature extraction stage uses anisotropic diffusion to enhance the images and a Mixture of Gaussians model to segment the dental work. The matching stage has three sequential steps: tooth-level matching, computation of image distances, and subject identification.

In year 2006, Eyad Haj Said, Diaa Eldin M. Nassar and Gamal Fahmy perform a work on “Teeth Segmentation in Digitized Dental X-Ray Films Using Mathematical Morphology” [2] In this paper they offer a mathematical morphology approach to the problem of teeth segmentation, Teeth segmentation from dental radiographic films is an essential step for achieving highly automated PM identification. They also proposed a grayscale contrast stretching transformation to improve the performance of teeth segmentation.

In year 2008, R. F. Silva, S. D. Pereira and F. B. Parado perform a work on “Forensic Odontology Identification Using Smile Photograph Analysis” [3] they proposed a concept of identification of unknown human by smile photographs that show specific characteristics of each individual has found wide acceptance all over the world. Therefore this paper shows this situation reporting different cases which smile photograph analysis were crucial to determine the positive identification of unidentified human bodies. All the cases were subjected to personal identification by photographs of smile including one adult male found in an advanced stage of decomposition, one adult female disappeared during an ecotourism trip, and one carbonized body of a male individual found in a forest region. During the autopsy the photographs of the smile were used by comparison of the ante and post-mortem images gave accurate and useful information not only about dental state but also the anatomical features surrounding the upper and lower anterior dental arches.

In year 2010, R. L. R. Tinoco, E. C. Martins and E. Daruge perform a work on “Dental Anomalies And Their Value in Human Identification” [4] This paper illustrates a positive identification case achieved by the diagnosis of an anomaly of tooth position, with confirmation using skull-photo superimposition. Even though forensic science presents modern techniques, in this particular case, the anomalous position of the canine played a key role on the identification, showing that the presence of a forensic dentist on the forensic team can be of great value.

In year 2010, Anny Yuniarti, Anindhita Sigit Nugroho, Bilqis Amaliah, Agus Zainal Arifin perform a work on “Classification and Numbering of Dental Radiographs for an Automated Human Identification System” [5] In this paper they developed an automated human identification system based on dental radiographs which has two main stages. The first stage is to arrange a database consisting of labelled dental radiographs. The second stage is the searching process in the database in order to retrieve the identification result. Both stages use a number of image processing techniques, classification methods, and a numbering system in order to generate dental radiograph's features and patterns. The first technique is preprocessing which includes image enhancement and binarization, single tooth extraction, and feature extraction. Next, we performed dental classification process which aims to classify the extracted tooth into molar or premolar using the binary support vector machine method. After that, a numbering process is executed in accordance with molar and premolar pattern obtained in the previous process.

In year 2012, Surendra Ramteke, Rahul Patil and Nilima Patil perform a work on “A STATE OF ART AUTOMATED DENTAL IDENTIFICATION SYSTEM (ADIS)” [6] This paper address review of new methodologies for post-mortem Identification Using dental records that means the Automated Dental Identification System (ADIS) can be used by Law enforcement agencies to locate missing persons also to identify Victims in Mass disasters (e.g. earthquakes, Tsunami, airplane Crash etc.) Using databases of dental X-rays. In PM identification, forensic odontologists rely mainly on dental radiographs, among other types of records (e.g., oral photographs, denture models, and CAT scans) to compare the morphology of dental restorations of unidentified individuals to choose those of candidates in the missing persons file. This paper reviews the new methods & techniques in which Identification is carried out by Comparing post Mortem (PM) images with Ante mortem (AM) dental records of missing people to find similar records.

In year 2013, Martin L. Tangel, Chastine Faticah, Fei Yan and Kaoru Hirota perform a work on “Dental Classification for Periapical Radiograph Based On Multiple Fuzzy Attribute” [8] this paper proposed dental classification for periapical radiograph based on multiple fuzzy attribute, where each tooth is analyzed based on multiple criteria such as area/perimeter ratio and width/height ratio. A classification method on special type of

dental image called periapical radiograph is studied and classification is done without speculative classification (in case of ambiguous object), therefore an accurate and assistive result can be obtained due to its capability to handle ambiguous tooth.

III. METHODOLOGY

The proposed system has mainly two modules: tooth shape extraction and tooth shape matching For individual identification, exact shape information is needed. It can be done in two ways. One method is contour-based and the other one is skeleton based. As like shape extraction, shape matching is the next desirable factor. Shape matching is one of the fundamental problems in computer vision. In the literature survey many algorithms were developed for dental radiographs identification but they are having some limitations, to overcome this, SBGFRLS algorithm is used here.

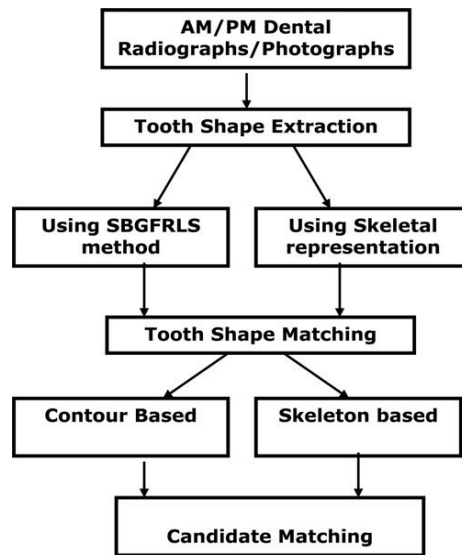


Fig 1: PIPELINE OF THE PROPOSED METHOD

1) Shape extraction

For individual identification, exact shape information is needed. It is done here in two ways. One method is contour-based and the other one is skeleton based

a) SBGFRLS method

In this section, a region-based active contour model with a SBGFRLS method is introduced. It uses a new region-based SPF function, which can efficiently stop the contours at weak or blurred edges. The advantage of this technique is automatically detecting the interior and exterior boundaries with the initial contour being anywhere in the image. It is possible to segment not only the desired object but also the other objects. By combining the geodesic active contour and Chan–Vese contours, a SPF function is designed [24]. It modulates the signs of the pressure forces inside and outside the region of interest so that the contour shrinks when outside the object or expands when inside the object. The signal flow graph of SBGFRLS method is shown in Fig.2, The SPF function is

$$SPF(I(X)) = \frac{I(x) - \left(\frac{c1+c2}{2}\right)}{\max\left(I(x) - \left(\frac{c1+c2}{2}\right)\right)}$$

where $I(x)$ is the region of interest of the image; $c1$ and $c2$ are the two constants which are the average intensities inside and outside the contour, respectively. In the Chan–Vese model, the constants $c1$ and $c2$ are computed using level set method.

b) Skeletal representation:

Skeleton is a nice shape descriptor because skeleton matching can perform as part matching, that is, part of the whole image may be used as the region for matching. Another advantage of skeleton matching is that, it is an intuitive representation of shape and can be understood by the user, allowing the user to be more controlled in the matching process. Skeleton is obtained using iterative thinning operation. Thinning is a morphological operation, which is used to remove some selected foreground pixels from the binary image. It is commonly used to tidy up the output of edge detectors by reducing all lines to single pixel thickness.

2) Shape matching

As like shape extraction, shape matching is the next desirable factor. Shape matching is one of the fundamental problems in computer vision. In this work, it is achieved in two ways. It is observed with both distance measures and then skeletal measures to make obvious decision about victim identification.

a) Contour matching with distance metric:

The ante-mortem dental records might have captured a long before than the post mortem images. Hence the viewing angle might be differing in both the dental records. So, there is a necessity of applying a rigid transformation to both ante mortem and post mortem images before finding the distance. The matching distance obtained can be improved by the rigid transformation. It is of the form

$$x' = Rx + t$$

where x' is the transformation on x , R is the transformation matrix and t is the translation vector.

b) Skeletal-based matching:

In conventional methods, computing a set of skeletal nodes, connecting the nodes into a graph and then indexing into a database and verification with one or more objects is followed. In this paper additional parameters are considered for skeleton matching. They are (i) the centroid, (ii) distance of the skeleton end point from the origin (iii) length of the skeleton and (iv) angle of skeleton end point with respect to the reference point.

IV. RESULTS

As a part of survey of various dental photographs, the author has implemented some of the steps like, contour and skeletons of the given radiographs and results are as follows

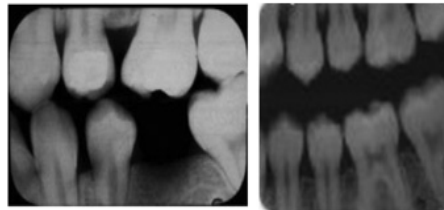
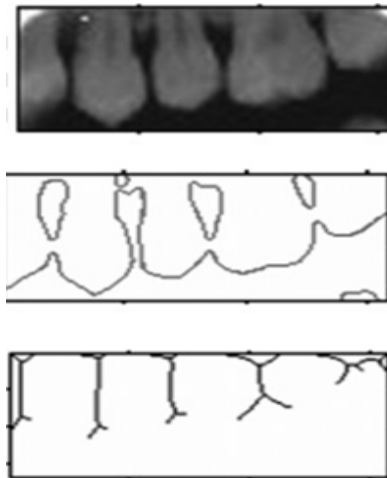


Fig: Sample input radiographs taken



Contour and Skeletons obtained for the given radiographs

V. CONCLUSION

Developing an automated dental identification system is a demanding challenge at present. In this paper a novel shape matching algorithm using skeleton is proposed for dental images. The contour tracing is implemented using a level set method named SBFRLS method. This contour tracing algorithm holds good even for bitewing images with dental works. Since matching with contour alone may not produce convincing results, an additional information using skeleton is worn in this paper. The experimental results clearly show that the algorithm which is adapted to radiographic images will be suit for photographic images with fewer computations. The precision and overall measures are higher for skeleton than contour, while considering the whole image, either maxilla or mandible separately for matching. Whereas for individual tooth, radiographic images with contour based approach is better than photographic images.

REFERENCES

- [1] Hong Chen and Anil K. Jain “Dental Biometrics: Alingment and Matching of Dental Radiographs” IEEE TRANSACTIONS ON PATTERN ANALYSIS AND MACHINE INTELLIGENCE, VOL 27, NO 8, AUGUST 2005
- [2] Eyad Haj Said, Diao Eldin M. Nassar and Gamal Fahmy “Teeth Segmentation in Digitized Dental X-Ray Films Using Mathematical Morphology” IEEE TRANSACTION ON INFORMATION FORENSIC AND SECURITY 2006
- [3] R. F. Silva, S. D. Pereira and F. B. Parado “Forensic Odontology Identification Using Smile Photograph Analysis” J Forensic Odontostomatol 2008;27:1:12-17
- [4] R. L. R. Tinoco, E. C. Martins and E. Daruge “Dental Anomalies And Their Value in Human Identification ” J Forensic Odontostomatol 2010;28:1:39-43
- [5] Anny Yuniarti, Anindhita Sigit Nugroho, Bilqis Amaliah, Agus Zainal Arifin “Classification and Numbering of Dental Radiographs for an Automated Human Identification System” TELKOMNIKA Vol. 10, No. 1, March 2012, pp 137-146
- [6] Surendra Ramteke, Rahul Patil, Nilima Patil, “A STATE OF ART AUTOMATED DENTAL IDENTIFICATION SYSTEM (ADIS)” Advances in Computational Research Volume 4, Issue 1, 2012
- [7] Savio C., Merlati G., Dancesino P., Fasina G., Menghini P., “Radiographic Evaluation of Teeth subjected to High temperature experiment study to aid identification process” Forensic science. Int., 2006, 158 (2), pp 108-116
- [8] Martin L. Tangel, Chastine Fatichah, Fei Yan, Kaoru Hirota “Dental Classification for Periapical Radiograph Based On Multiple Fuzzy Attribute” IEEE 2013
- [9] Pushparaj, V., Gurunathan, U., Arumugam, B., “Human Forensic Identification using similarity and distance metrics” 8th Annual IEEE India Conference INDICON, Cochin, India 2012