

International Journal of Computer Science and Mobile Computing



A Monthly Journal of Computer Science and Information Technology

ISSN 2320-088X

IMPACT FACTOR: 5.258

IJCSMC, Vol. 5, Issue. 9, September 2016, pg.103 – 108

64-Slice Computed Tomography

Amruta A. Choudhari

B.E. in Information Technology, Chikhali (S.G.B.A.U.)

Choudhariamruta29@rediffmail.com

Abstract: — *This paper gives knowledge about advanced technology in computed tomography, i.e. CT-Scan. This technology is great application of image processing. This paper gives detail information about working CT-Scanner, use of X-Ray in CT-Scan and working of 64-slice computed tomography. Study of this paper provides information about great application of image processing in biomedical field as well as aware people about 64-slice computed tomography. It is most efficient way for prediction of diseases. This new technology provides a noninvasive method to directly visualize the coronary arteries. This is faster scanning method which significantly increases patient comfort [1].*

Keywords—“64-slice, computed tomography, x-ray, detector, 3-dimensional”

I. INTRODUCTION

64slice computed tomography (CT) scan is a radiological test used to assess the health of the heart in patients who have chest pain or shortness of breath. This rapid, noninvasive procedure allows early diagnosis and intervention for heart patients. Similar to a standard CT scan, the 64 slice CT scan produces real-time cross-sectional images detailing the cardiac anatomy and blood flow [6]. 64-slice computed tomography based on CT-Scan hence we firstly need to understand about computed tomography. Computed Tomography (CT) imaging is also known as "CAT scanning" (Computed Axial Tomography). Tomography is from the Greek word "tomos" meaning "slice" or "section" and "graphic" meaning "describing".

II. RELATED WORK

A. Computerized Tomography Scan

(CT) — Formally known as computerized axial tomography or (CAT) — is a type of radiographic imaging procedure that takes many pictures of a given area for optimal evaluation of body structures. The many images generated from a CT scan can be manipulated on the computer to create different axial views of the body. In other words, the body's interior can be viewed along different axes, or planes, for comparison.

B. What is Computed Tomography?

Computed tomography (CT) is an imaging procedure that uses special x-ray equipment to create detailed pictures, or scans, of areas inside the body. Each picture created during a CT procedure shows the organs, bones, and other tissues in a thin “slice” of the body. The entire series of pictures produced in CT is like a loaf of sliced bread—you can look at each slice individually (2-dimensional pictures), or you can look at the whole loaf (a 3-dimensional picture). Computer programs are used to create both types of pictures.

Most modern CT machines take continuous pictures in a helical (or spiral) fashion rather than taking a series of pictures of individual slices of the body, as the original CT machines did. Helical CT has several advantages over older CT techniques: it is faster, produces better 3-D pictures of areas inside the body, and may detect

small abnormalities better. The newest CT scanners, called multislice CT or multidetector CT scanners, allow more slices to be imaged in a shorter period of time.

C. Working of CT

Computed Tomography is based on the x-ray principal: as x-rays pass through the body they are absorbed or attenuated (weakened) at differing levels creating a matrix or profile of x-ray beams of different strength. This x-ray profile is registered on film, thus creating an image. In the case of CT, the film is replaced by a banana shaped detector which measures the x-ray profile. In the case of CT, detector is present in particular shape. A CT Scanner looks like a big, square doughnut. The patient aperture (opening) is 60 cm to 70 cm (24" to 28") in diameter. Inside the covers of the CT Scanner is a rotating frame which has an x-ray tube mounted on one side and the banana shaped detector mounted on the opposite side. A fan beam of x-ray is created as the rotating frame spins the x-ray tube and detector around the patient. Each time the x-ray tube and detector make a 360° rotation, an image or "slice" has been acquired. This "slice" is collimated (focused) to a thickness between 1 mm and 10 mm using lead shutters in front of the x-ray tube and x-ray detector.

As the x-ray tube and detector make this 360° rotation, the detector takes numerous snapshots (called profiles) of the attenuated x-ray beam. Typically, in one 360° lap, about 1,000 profiles are sampled. Each profile is subdivided spatially (divided into partitions) by the detectors and fed into about 700 individual channels. Each profile is then backwards reconstructed (or "back projected") by a dedicated computer into a two-dimensional image of the "slice" that was scanned.

D. Adverse effect of radiation from CT

Some people may be concerned about the amount of radiation they receive during CT. CT imaging involves the use of x-rays, which are a form of ionizing radiation. Exposure to ionizing radiation is known to increase the risk of cancer. Standard x-ray procedures, such as routine chest x-rays and mammography, use relatively low levels of ionizing radiation. The radiation exposure from CT is higher than that from standard x-ray procedures, but the increase in cancer risk from one CT scan is still small. Not having the procedure can be much more risky than having it, especially if CT is being used to diagnose cancer or another serious condition in someone who has signs or symptoms of disease.

It is commonly thought that the extra risk of any one person developing a fatal cancer from a typical CT procedure is about 1 in 2,000 [2]. In contrast, the lifetime risk of dying from cancer in the U.S. population is about 1 in 5. It is also important to note that everyone is exposed to some background level of naturally occurring ionizing radiation every day. The average person in the United States receives an estimated effective dose of about 3 millisieverts (mSv) per year from naturally occurring radioactive materials, such as radon and radiation from outer space. By comparison, the radiation exposure from one low-dose CT scan of the chest (1.5 mSv) is comparable to 6 months of natural background radiation, and a regular-dose CT scan of the chest (7 mSv) is comparable to 2 years of natural background radiation.

The widespread use of CT and other procedures that use ionizing radiation to create images of the body has raised concerns that even small increases in cancer risk could lead to large numbers of future cancers. People who have CT procedures as children may be at higher risk because children are more sensitive to radiation and have a longer life expectancy than adults. Women are at a somewhat higher risk than men of developing cancer after receiving the same radiation exposures at the same ages. We have to take doctor permission before doing CT-Scan. People considering CT should talk with their doctors about whether the procedure is necessary for them and about its risks and benefits. Some organizations recommend that people keep a record of the imaging examinations they have received in case their doctors don't have access to all of their health records. A sample form, called My Medical Imaging History, was developed by the Radiological Society of North America, the American College of Radiology, and the U.S. Food and Drug Administration. It includes questions to ask the doctor before undergoing any x-ray exam or treatment procedure.

III. 64-SLICE COMPUTED TOMOGRAPHY

A 64-slice CT scanner is a device that can gather high resolution images of parts of the body, such as the heart, brain and the lungs in less than 5 seconds. It has led to advancements in cardiovascular diagnosis and is a less invasive procedure [3]. A 64 slice CT heart scan is performed to evaluate the arteries of the heart, and can also be used to assess the function of the heart, the anatomy of the heart, and the degree of coronary calcification in the heart. The arteries of the heart are known as coronary arteries, and extend from the aorta to supply the heart itself with blood. These vessels are filled when the heart is relaxed.

64-Slice CT heart scans can detect disease in the coronaries that has resulted in narrowing of the arteries, which is usually created by atherosclerosis. This process occurs to some extent in all individuals, though it may be accelerated in those with high "cholesterol" levels (especially LDL). The end result is the creation of a

"plaque" or narrowing of the coronary artery. If the coronary arteries become narrowed, the decreased blood flow to the heart may be felt as pain. If the coronary arteries are completely blocked, a heart attack will occur. If coronary artery disease is detected on your heart scan, you may be a candidate for an interventional procedure or surgery before a heart attack occurs. Overall, the primary benefit of a 64 slice CT scan is the prevention of a heart attack.

64 slice CT scans can also be used to evaluate the function of the heart. Images are re-created in real-time, and can be played as a video clip that show the movement of the heart during the heartbeat. If a patient has suffered a heart attack, the cardiac function will be altered, which can be seen on the cardiac function images. A 64 slice CT scan can thus be used to evaluate congestive heart failure, which is usually caused by a prior heart attack. 64-slice CT heart scans provide beautiful images of heart anatomy. This may be useful to your physician if you have congenital heart disease, which is abnormal heart disease that has been present since birth. A heart scan may detect a patent foramen ovale [6].

Finally, 64-slice CT heart scans can provide a calcium score. The calcium score represents the amount of calcium that has built up in your heart. The higher the level of calcium, the higher your chance of narrowing in your arteries which may result in a heart attack.

A. What is a 64 CT Scan?

In computed tomography (CT) scanning, x-rays obtain image data from different angles around the body and then are processed by a computer. The images are 3 dimensional in nature and provide good resolution. The CT is an excellent technique to make a diagnosis of disorders in many different parts of the body, however, because the heart is constantly beating, CT scan could never be used to image it in the past. Until the past few years, the technical gold standard was 16-slice CT scan, which required the patient to hold their breath for 25- to 40-seconds in the time it took to perform the scan. Today, the 64 slice CT scanner can perform the same task in just a few seconds and the images are much better.

A 64 Computed Tomography (CT) scan refers to the newest generation in CT scan technology, and is also known as "64-slice CT." The 64 "slices" refer to the number of detectors that are present on a CT scanner. While original tomography scanners used only one detector to pick up information, Multi-Detector Computed Tomography (MDCT) uses multiple detectors to create images of the body. This technology increases both "spatial" and "temporal" resolution, which means that we can create more detailed images in a shorter amount of time [2]. One of the major advances with 64 slice CT scanning has been vast improvements in cardiac. The heart is difficult to visualize because it remains in movement, constantly changing in shape and size as the heart beats. In addition, the structures of interest (coronary arteries) are small structures that have a width measured in millimeters. With new generation 64 slice CT heart scans, cardiologists and radiologists can evaluate the coronary arteries and determine if there is atherosclerosis in the arteries of the heart. While there is still controversy regarding the utility of 64 CT heart scans as a screening procedure, heart scans provide useful information that may ultimately prevent a heart attack.

B. Working of 64-Slice CT

During a computed tomography (CT) scan, the scanner rotates around the patient and takes a large number of x-ray images. These x-ray images are then sent to a computer for processing. Because the x-ray images are taken from a variety of angles, the computer is able to put them together and create a 3-dimensional image of the patient. Unlike a traditional "x-ray," which is taken in only 2-dimensions, this allows the physician to look at the arteries and other organs in the body from essentially any direction, which is extremely valuable in the diagnosis of disease [5].

C. Advantage of a 64 slice CT Scanner

Today, the only way to confirm the presence of coronary artery disease is to get what is called a cardiac catheterization. This invasive procedure requires a large amount of dye, large needle in the groin, bed rest for 6-8 hours and an overnight stay in the hospital. The 64 slice CT scanner is so fast that it can image the heart and the coronary vessels in a few seconds. This latest generation scanner is able to non-invasively capture images of any organ in one second and capture images of the heart and coronaries in fewer than five heartbeats, something no other CT system can offer. Because the 64 slice CT scanner has only been recently available, its use in the evaluation of the heart has been limited. However, there is no doubt that it will soon replace cardiac catheterization for many elective cases. Heart catheterization is a very commonly performed test that is safe and provides very accurate information. But, it is still an invasive test, which is one reason why this technology is being studied. The unprecedented coverage speed of this system allows physicians to capture a high-resolution image of the heart in 5 beats, or go head to toe in less than 10 seconds - faster than any other CT scanner on the Market today.

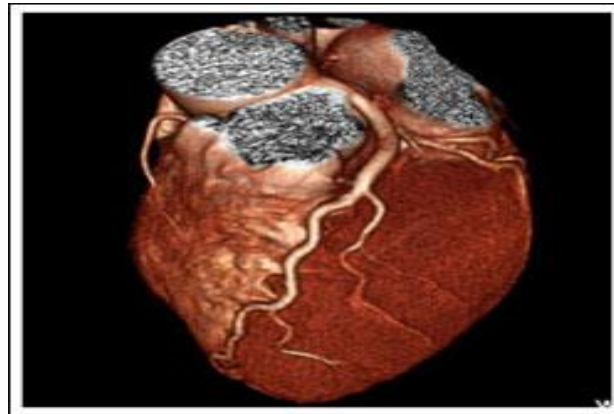


Figure 1.: Sample of image taken by 64 slice CT

This pain-free procedure offers exceptional image quality which can mean better physical diagnosis, faster recovery time & increase patient comfort & convenience. By providing non-invasive study that can quickly distinguish blocked from normal coronary arteries. It can determine who is & is not at high risk of having a heart attack. This can reduce a time a patient must spent in emergency department or eliminate the need for hospitalization. Unlike conventional angiogram, the needle is placed in the hand and unlike conventional angiogram; the needle is placed in the hand and not in the groin. Unlike cardiac catheterization, this is an outpatient procedure.

The complications of the procedure itself are much less than that of a cardiac catheterization. For those who have back or neck pain, this technique is much easier than a cardiac catheterization as the procedure takes a few seconds[2].The complications of the procedure itself are much less than that of a cardiac catheterization. For those who have back or neck pain, this technique is much easier than a cardiac catheterization as the procedure takes a few seconds [2].

D. Difference between 64 slice scanner and other multidetectors

The major difference is the speed to complete a given volume coverage and the resolution achieved. An advantage of the reduced time is that the artifacts produced by the movement of the patient are minimized. For organs as the heart or the lungs, this is very important, because they naturally move when they function. Especially when using contrast you want to complete the scan in the shortest time possible. The number refers to the quantity of detector rings. With the 16-slice you can obtain 16 simultaneous thin images of the desired area, with the 64-slice, 64, so you can have a better resolution and more information to construct the 3D visualization.

When you have a CT scan, you're not just having a single picture taken of your brain. A series of scans is done. For example, if it's a head CT, scans will be taken starting at the top of the brain and moving down to the brain stem. A 16 slice CT scanner has more space between the slices than a 64 slice scanner. Fewer slices mean more space between the slices and a greater chance of missing something small that might fall between the slices. This may or may not matter depending on the reason for the scan[3].

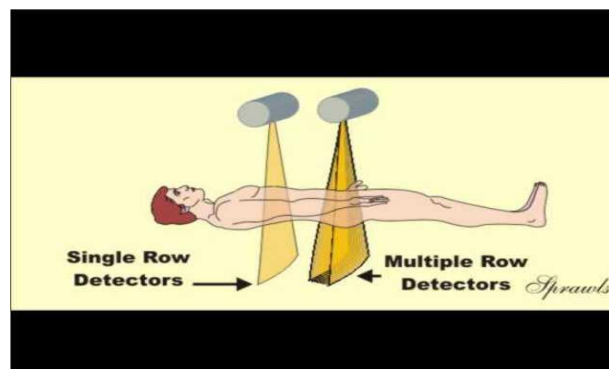


Figure2: single row multi row detector

A single slice or a non-multi-slice CT scanner takes only one slice or image as the X-ray beam makes a complete rotation around you. A 64 slice CT scanner can take up to 64 slices or images in one rotation. The more detectors a CT scanner has, the more slices per rotation it is able to acquire. The number of slices per rotation is equal to the number of detectors the scanner has. If a CT scanner has 16 detectors, it is able to take 16 slices per rotation; if it has 64 detectors, it can acquire 64 slices of anatomy per rotation and so on. A detector is a device that reads or detects the amount of x- ray that passes through the object being scanned. The addition of detector to the CT-Scan meant that more anatomy could be visualized in shorter amount of time and in greater detail. Arteries could now Scan opened up an area now call CTA or Computed Tomographic Angiography. (The study of arteries) 64 slice CT scan is now being used in the study of the arteries of the heart called coronary CTA or cardiac CTA. The introduction of 64-slice cardiac CT allows nearly all patients to be scanned with very high resolution. High resolution allows visualization of the entire coronary tree with high accuracy and detail. Plaque and calcifications can be visualized and used to determine the extent of coronary disease.

E. Discussion

This systematic review showed that 64-slice CT angiography has high diagnostic accuracy in the detection of CAD. In comparison to earlier scanners such as 4-slice and 16-slice CT, 64-slice CT angiography has demonstrated significant improvement in the assessment of coronary artery branches, including distal segments. Studies performed on the 16-slice CT scanners in the detection of CAD showed that the sensitivity of MSCT angiography decreased when assessing the distal coronary segments due to limited spatial and temporal resolution [7]. However, this was not observed in this study since no significant difference was found when comparing proximal with middle or distal segments. In comparison to 16-slice MSCT scanners, the current 64-slice scanner has increased slices per gantry rotation and fast gantry speed (330 ms/rotation versus 375), which translate into superior spatial resolution (0.4mm versus 0.75) and temporal resolution (83 or 165 versus 188 ms). The reduction in voxel size allows acquisition of isotropic volume data and makes distinction between hypo intense soft plaque and contrast enhanced blood more evident. Moreover, more coronary segments can be assessed with 64-slice CT angiography with the percentage of assessable segments being higher than that from 16-slice scanners. Percentage of assessable segments was significantly higher than that of 16- and 4-slice scanners as shown in our results (96% versus 92% and 74%)[8].

Recent studies have reported that two major limitations for affecting the MSCT evaluation of coronary artery segments are motion artifacts and severe coronary calcifications. In order to reduce motion artifacts, blockers were commonly used prior to CT examination, even if in the 64-slice scanners, as shown in the results. Consistent use of β -blocking agents before the scan to keep patients' heart rates below 60 bpm could produce better results in some studies. The latest development of dual source CT has been reported to improve temporal resolution when compared to early 64-slice scanners, and coronary arteries were visualized without motion artifacts at any heart rate and beta-blocker utilization could be discarded [9,10]. Initial experience on dual source CT showed the advantages of imaging patients with high heart rates and reduction of occurrence of motion artifacts in comparison to earlier 64-slice scanners [10], although further studies need to be performed to establish the diagnostic accuracy of dual source CT in the diagnosis of CAD. Only one study performed on a dual source MSCT was included in our analysis, therefore, a comparison between dual source CT and earlier 64-slice scanners cannot be performed, although dual source demonstrated improved results even if in patients with higher heart rate. Another common factor that affects evaluation of coronary artery lumen is the presence of extensive calcification. Similar to 4-slice and 16-slice CT, extensive artery calcifications are a frequent source for impairing vessel assessment, even with 64-slice CT, although the degree of artifacts due to partial volume effects seem to be less severe. Severe calcification obscures coronary lumen and can lead to overestimation of the severity of the lesions due to blooming artifacts; making quantification of the degree of coronary artery stenosis is difficult. The interference of calcification with assessment of coronary artery lumen was reported in three studies, and results showed that the specificity was decreased with the increase of the calcium score, indicating the relatively high false positive cases in the presence of extensive calcification. Thus, caution should be taken into account in imaging patients with severe calcification. Body mass index (BMI) seems to be another factor that may affect the diagnostic accuracy of 64-slice CT in the detection of CAD. This was investigated in one study which demonstrated the relationship between BMI and diagnostic value of 64-slice CT [13]. Relevant research has been performed to investigate the relationship between body weight/BMI and image noise for reduction of radiation exposure without loss of diagnostic information in CT scanning protocols [11, 12]. Yoshimura et al recently reported that image noise correlated well with body weight in coronary MSCT angiography [11]. Therefore, relationship between radiation dose, image noise and diagnostic accuracy should be investigated to minimize radiation dose while maintaining adequate diagnostic information for clinical investigation of coronary artery disease. It must be noted that in practice, MSCT angiography is more likely to be applied to patients who have low to intermediate probability of CAD. While the negative predictive value.

IV. CONCLUSION

Finally we conclude that 64 slice computed tomography shows that it is very efficient and convenient way for prediction of diseases .64 slice computed tomography is also a time saving technique. Since it is painless technique patient comfort get increases.

64 Slice CT has high diagnostic accuracy in detection of diseases. In addition, we can scan a patient with a complete 64-slice CT scan in fewer than 10 seconds. This means that even patients with severe breathing problems are able hold their breath for the required time. With traditional CT, lesions and nodules can be missed while a patient is taking a breath. 64-slice CT reveals encouraging results to non invasively detect different types of coronary plaques located in the proximal coronary system. The ability to determine plaque burden currently is hampered by mainly an insufficient reproducibility.

REFERENCES

- [1] www.stfrancisheartcenter.com/chsli/sfh/live/images/pdf/.../64slice.pdf
- [2] http://www.scandirectory.com/content/64_slice_ct.asp
- [3] <http://askville.amazon.com/difference-16-slice-ct-scanner64/AnswerViewer.do?requestId=4600650>
- [4] www.64ctscan.com/64_Slice_CT_Heart_Scan_2384.html
- [5] http://www.64ctscan.com/64_slice_ct.html
- [6] <http://www.ct-scan-info.com/64slicect.html>
- [7] Stein PD, Beemath A, Kayali F, et al. Multidetector computed tomography for the diagnosis of coronary artery disease: a systematic review. *Am Heart J* 2006; 119:203–16.
- [8] Sun Z, Jiang W. Diagnostic value of multislice CT angiography in coronary artery disease: a meta-analysis. *Eur J Radiol* 2006; 60:279– 86.
- [9] Flohr TG, McCollough CH, Bruder H, et al. First performance evaluation of a dual-source CT (DSCT) system. *EurRadiol* 2006; 16:256– 68.
- [10] Achenbach S, Ropers D, Kuettner A, et al. Contrast-enhanced coronary artery visualization by dual-source computed tomography-initial experience. *Eur J Radiol* 2006; 57:331–5.
- [11] Yoshimura N, Sabir A, Kubo T, et al. Correlation between image noise and body weight in coronary CTA with 16-row MDCT. *AcadRadiol* 2006; 13:324–8.
- [12] Das M, Mahnken AH, Muhlenbruch G, et al. Individually adapted examination protocols for reduction of radiation exposure for 16-MDCT chest examinations. *Am J Roentgenol* 2005;184:1437–43
- [13] Raff GL, Gallagher MJ, O’Neill WW, et al. Diagnostic accuracy of noninvasive coronary angiography using 64-slice spiral computed tomography. *J Am CollCardiol* 2005; 46:552–7.
- [14] http://en.wikipedia.org/wiki/X-ray_computed_tomographyen.wikipedia.org/wiki/X-ray_computed_tomography-Similar to X-ray computed tomography - Wikipedia, the free encyclopedia.